

‘A Safety Armor In Restorative Procedures: R.D.T’

Dr. Divya Singh¹, Dr. Pooja Kabra², Dr. Ekta Choudhary³

ABSTRACT:

Preserving the residual dentin after cavity or root canal preparation is of paramount importance as it directly impacts both pulp vitality and the permeability of dentin to oral fluids. These factors ultimately influence the tooth's resistance to fractures. Successful endodontic therapy requires a comprehensive understanding of root canal anatomy. It is crucial to maintain the thickness of the root canal wall, as any misjudgements in this regard can result in issues such as soft tissue involvement during cavity preparation or strip perforation during root canal preparation.

Keywords: remaining dentin thickness, iatrogenic factor, measurement of RDT, root canal.

INTRODUCTION: With the knowledge of current concept, the primary goal of any restorative or endodontic treatment is to preserve the RDT. This aspect holds particular significance in any restorative procedure, particularly in the context of safeguarding the overall tooth structure.

Ensuring the preservation of an appropriate thickness of residual dentin is imperative for upholding the structural integrity of the tooth. It provides support and helps prevent fractures, ensuring the tooth can continue to function effectively. Too much dentin removal can weaken the tooth, so it's a delicate balance between thorough cleaning and preservation.

EFFECT OF REMAINING DENTIN THICKNESS ON DENTIN AND DENTAL PULP

The thickness of the remaining dentin plays a crucial factor that significantly influences the health of dentin and dental pulp. A decrease in the thickness of remaining dentin correlates with a reduction in the number of odontoblasts which leads to more immediate infiltration of bacteria from oral fluid, potentially triggering inflammatory responses within the dental pulp.

Historically, research studies hence put forth recommendations for maintaining RDT of 2mm to ensure the protection of the pulp. While some have advocated for a minimum of 1mm, the current consensus acknowledges a minimum thickness of 0.5mm. When a lesion encroaches within 0.25mm to 0.3mm of the pulp, inflammatory responses associated with pulpitis and hyperemia are initiated.⁽¹⁾

The deposition of reactionary dentin is most pronounced within the range of 0.25mm to 0.5mm of remaining dentin thickness, a condition that can be exacerbated by the presence of bacteria. Remaining dentin thickness below 0.25mm has the potential to damage

¹Post graduate student

²Associate Professor

³Professor and Head

Author for correspondence: Dr. Pooja Kabra, Assoc.P rofessor, Department of Conservative dentistry and endodontics, SDS,Sharda University, Greater Noida

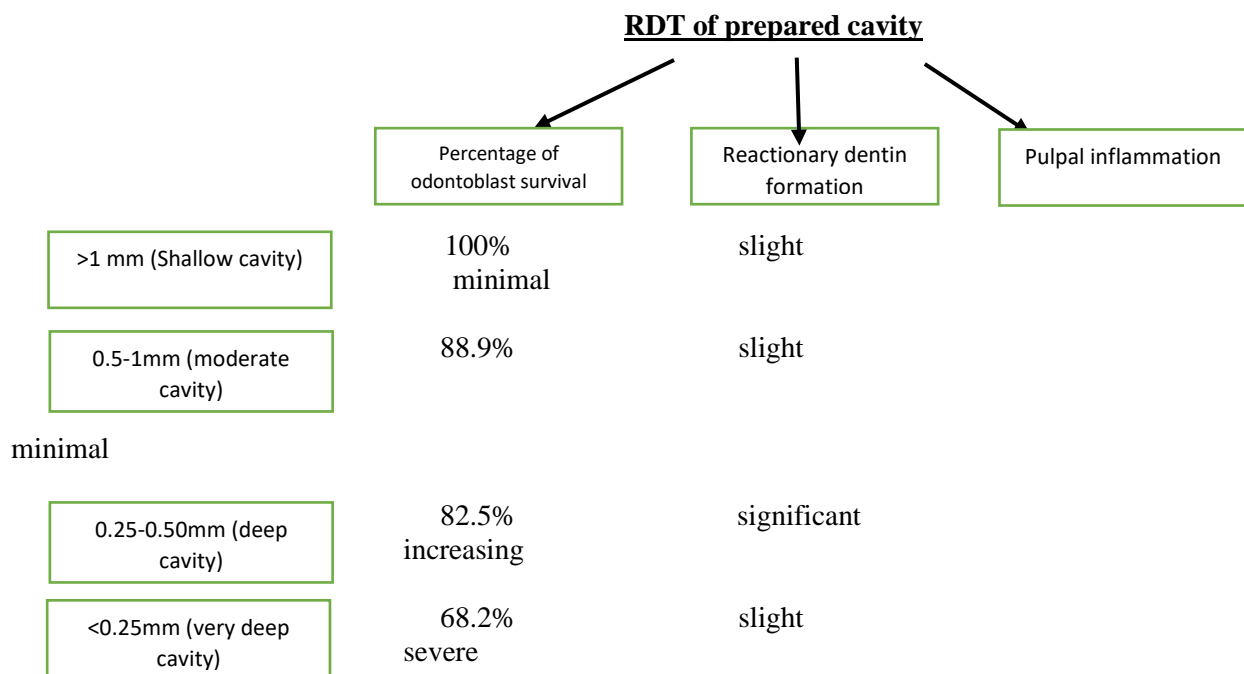
odontoblasts, impeding their secretory functions. At thickness of 0.5 mm and below, there is a notable reduction in odontoblast number by 33.7%, while a decrease of 13.6% is observed within the range of 0.25mm to 0.5mm.⁽²⁾

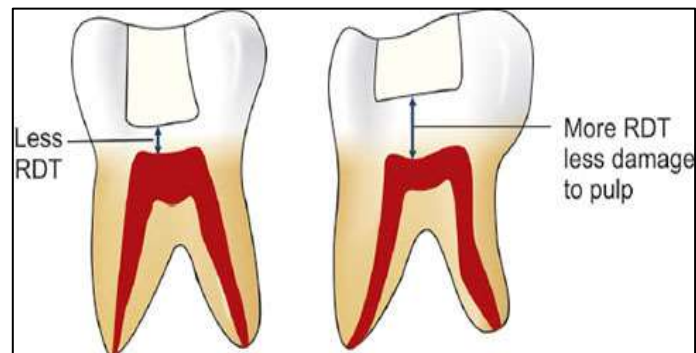
IMPORTANCE OF REMAINING DENTIN THICKNESS IN RESTORATIVE DENTISTRY:

RDT acts as a protective barrier for the dental pulp of dentin during restorative procedures helps safeguard the pulp from external stimuli, reducing the risk of post-treatment sensitivity and maintaining pulp vitality. With the decrease in thickness of remaining dentin, there is a concurrent reduction in the number of odontoblasts, thereby increasing the susceptibility to pulpal inflammation. Thick heightened vulnerability arises from the facilitated access to bacteria and their byproducts to the pulp and periradicular area. A sufficient RDT acts as a critical protective barrier against potential vibrational injuries and the frictional heat generated by dental burs during tooth or cavity preparation.⁽³⁾ Moreover, it functions as a defence mechanism against cytotoxic injuries that may arise from procedures like acid etching or the application of restorative materials. It also influences the bonding strength between restorative material and dentin. Insufficient dentin thickness can compromise the adhesive bond, leading to restoration failure.

Various authors have presented their perspective on RDT, suggesting that an RDT of at least 1mm is adequate to shield the pulp from cytotoxic effects caused by certain restorative materials, while an RDT of 2mm is recommended to protect the pulp from injuries resulting from both restorative materials and treatment procedures. Additionally, it is emphasized that an RDT of at least 0.5mm is necessary to prevent pulpal damage, whereas an RDT of less than 0.25mm may lead to inflammatory reactions within the pulp.⁽²⁻⁴⁾

The impact of RDT on odontoblast survival, the formation of reactionary dentin, and the occurrence of pulpal inflammation in a prepared cavity is a critical aspect of understanding the intricate dynamics involved in restorative dentistry which are as follows:





Different restorative materials have been shown in a very deep cavity (0.5mm) to evaluate the survival of odontoblast and these are:

Calcium hydroxide have shown 100% survival of odontoblast, so it is safe to use in a very deep cavity. Other restorative materials like polycarboxylate, zinc oxide, composite resin, and resin-modified GIC have shown 81.1%, 78.4%, 74.2%, and 43.1% survival of odontoblasts respectively. This shows that restorative materials like resin-modified GIC must be avoided in very deep cavity preparation because they are cytotoxic.⁽⁵⁾

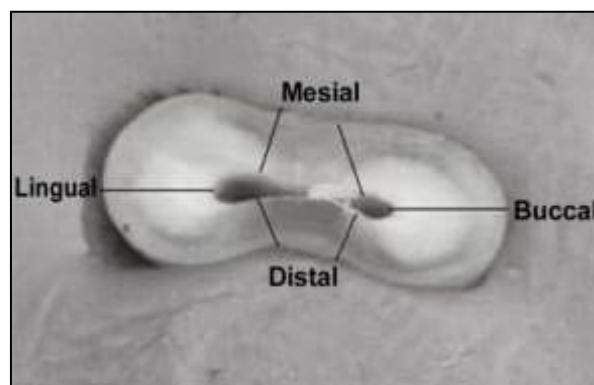
IMPORTANCE OF RESIDUAL DENTIN THICKNESS IN ENDODONTICS:

The importance of RDT in root canal treatment cannot be overstated, as it significantly influences the success and overall outcome of the procedure. Residual dentin contributes to the overall strength and stability of the tooth. During root canal preparation, careful consideration of RDT helps prevent excessive removal of dentin, which could weaken the tooth structure and increase the risk of fractures.

Maintaining an optimal RDT is crucial for preventing complications such as strip perforations. Excessive dentin removal, especially in critical areas known as “danger zones,” can compromise the tooth’s structural integrity and lead to undesirable outcomes.

The success of root canal treatment also depends on post-endodontic restoration. Preserving sufficient residual dentin provides a stable foundation for post-endodontic restorative procedures, ensuring long-term success and functionality.

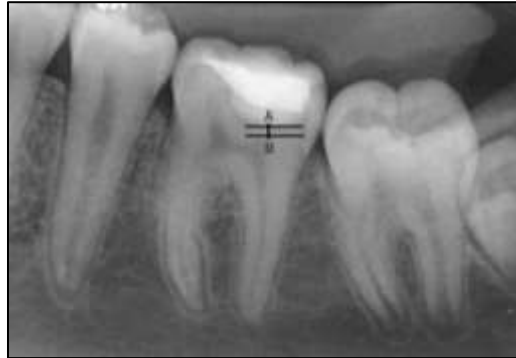Endodontic guidelines often recommended that a minimum thickness of dentin, typically around 1mm, should be maintained along the entire length of root canal after the completion of root canal procedures. This guideline aims to strike a balance between effective cleaning and shaping of the canal while preserving enough dentin to pulp protection.⁽⁶⁾



METHODS FOR ESTIMATION OF REMAINING DENTIN THICKNESS:

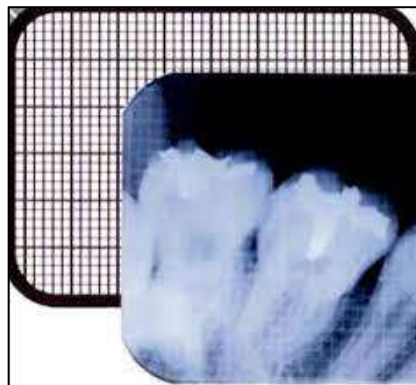
In the clinical context, various methods have been developed to estimate RDT during dental procedures. These methods aim to overcome the challenges associated with conventional techniques and provide more accurate and reliable estimations of RDT. The choice of method depends on factors such as the specific dental procedure, equipment availability, and the need for non-invasive measurements. These methods include:

1. **Radiographic method:** traditional X-ray techniques, such as intraoral periapical radiographs, have been historically used. However, these methods may have limitations due to inherent distortion such as elongation and foreshortening and challenges in accurately measuring the RDT.
2. **Radiographic grid method:** to overcome the constraints linked to traditional

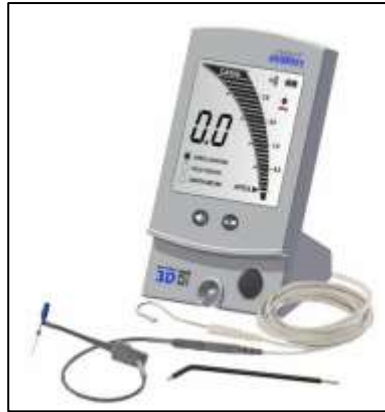

radiographic approaches, Everett and Fixot introduced a refinement in 1963 known as the radiographic grid method. This technique involved the integration of metallic grids into radiographs. However, the application of metal grids within the oral cavity presented practical challenges, and their inherent metallic nature posed issues during placement. Additionally, the high radiopacity of these grids resulted in the obscuration of anatomical structures, further complicating the accurate assessment of the radiographic image.⁽⁷⁾

3. **Digital radiographic technique:** utilizing digital technology, this method provides enhanced imaging quality and allows for more accurate assessments of RDT.



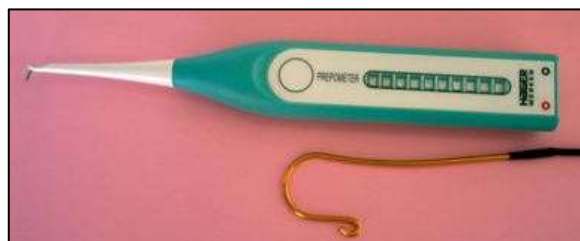4. **Transillumination techniques:** these involve passing light through the tooth to visualize and estimate the thickness of remaining dentin. Various devices and methods, such as Fiber-optic transillumination, have been explored for this purpose.
5. **EndoEst 3D:** this innovative method quantifies electric resistance within the dentin, offering a means to ascertain the thickness of remaining dentin. It provides a non-invasive approach to RDT measurement.



6. **Ultrasonic micrometer:** Baum et.al (1963)pioneered the utilization of a non-invasive ultrasonic diagnostic technique for dental applications. This technique involves essential components such as transducer, pulse receiver, and oscilloscope.



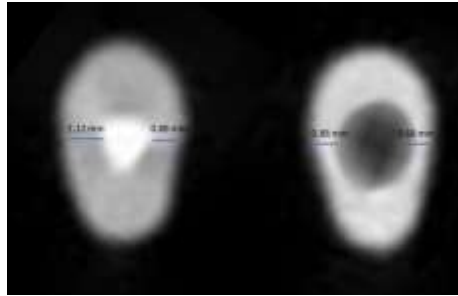
7. **Prepometer:** the device, created by Hager in 2007, is a battery-operated tool designed to control the depth of preparation through the utilization of colored light- emitting diodes. Primarily developed for assessing residual dentin thickness (RDT) during crown preparation, this instrument measures electric resistance to achieve its intended purpose.⁽⁸⁾
8. **Optical coherence tomography (OCT):** the application of OCT in dentistry commenced in California in 1998, introducing a non-invasive laser technique. This method, initially described by Fujita et al. in 2014, was specifically introduced for the measurement of RDT.



9. **Cone Beam Computed Tomography:** it produces 3-D images with a lower radiation dose in comparison to traditional computed tomography. The precision and efficiency of the 3-D images acquired through CBCT make it a valuable tool for evaluating residual dentin thickness. Additionally, CBCT allows for the comprehensive assessment of various aspects of the root canal system, including critical areas like middle of the root where root curvature is often found, commonly referred to as the

“danger zone”. This capability is particularly important for identifying and mitigating the risk of iatrogenic mishaps in such vulnerable regions.⁽⁹⁾

10. Micro-computed tomography & virtual simulation technique: this approach is non-invasive and non-destructive, offering a 3-D representation of the tooth. Utilizing 3D micro-computed tomography data, the software employs a direct ray casting technique to generate simulated 2D radiographs without the need for actual radiographic imaging. This simulated radiograph aids in the precise measurement of RDT.



11. Laser methods: Laser Doppler Flowmetry primarily used to assess pulp vitality, but laser techniques have also been investigated for estimating RDT. It measures blood flow in the pulp and indirectly provides information about the thickness of overlying dentin.

Among all these micro-CT gives more precise result than CBCT and other devices in evaluating RDT but it is not suitable for clinical use.⁽¹⁰⁾

CLINICAL CONSIDERATIONS IN PRESERVING REMAINING DENTIN THICKNESS:

1. Smart prep burs:

Although carbide dental burs are efficient in the removal of non-decalcified enamel and dentin, they lack the capacity to differentiate between carious and normal dentin during cavity preparation. Caries-affected dentin exhibits a Knoop hardness value in the range of 10-40 kg/sqmm, distinguishing it from healthy dentin, which typically falls within the range of 45-63 kg/sqmm.⁽¹¹⁾

The SmartPrep bur- like instrument, composed of a medical- grade polymer within a hardness less than that of healthy dentin, is specifically engineered for the selective removal of carious dentin. This is achieved by its intentional loss of cutting efficiency upon reaching caries-affected dentin. The bur blades employ a “plowing” mechanism, wherein carious dentin is initially compressed locally and subsequently pushed along the more resilient dentin surface, leading to rupture at this level. The loosened fragments are then transported to the surface.

Noteworthy advantages of SmartPrep bur include its ability to locate the orifice of the root canals with non-linear access, identify calcifications and obliterations, and reduce the risk of procedural errors such as gouging and strip perforation. Additionally, it aids in the preservation of more pericervical dentin.

Other burs that prevent the RDT are fissurotomy, SmartP, SmartBur II, and PolyBur P1.



2. Taper

It is crucial to acknowledge that no instrumentation method can achieve complete debridement of root canal walls. This underscores the significance of preventing procedural mishaps, such as deviation, zipping, or perforations, as these complications can pose challenges for effective disinfection. Preserving as much radicular dentin as possible is equally paramount to prevent root weakening and enhance fracture resistance. The establishment of a straight-line access to each canal becomes pivotal in preventing excessive thinning of radicular structures during instrumentation. Dentin thickness results from these procedures emerge as a key factor directly associated with a root's fracture resistance.⁽¹²⁾

Lim and Stock have advocated for a minimum RDT of 0.3mm, emphasizing its necessity for ensuring adequate fracture resistance and preserving canal wall integrity.

A recent study conducted by De-Deus and colleagues proposed that successive enlargement of root canals using instrument sizes 30/0.04 (S2) and 30/0.06 (S3) is anticipated to lead to a reduction in dentin thickness. Furthermore, this study indicated a shift in the position of the danger zone from the middle to the coronal third during such enlargements.

3. Access cavity preparation

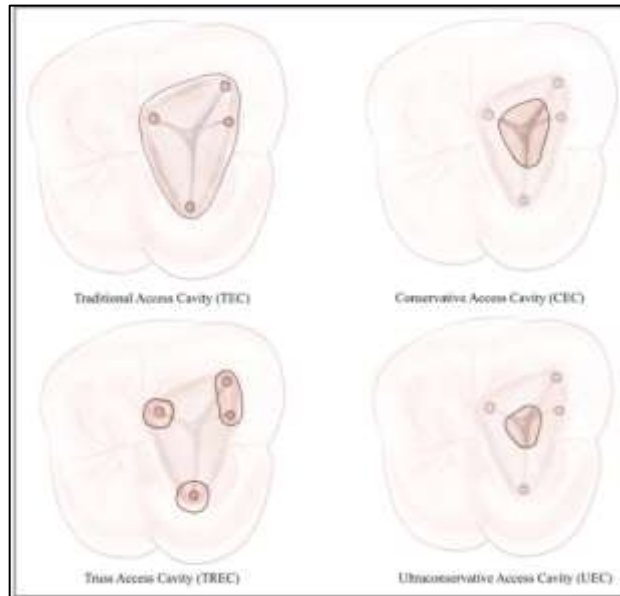
Traditional endodontic cavities (TECs) advocate for a straight-line access approach to enhance preparation efficacy, but implementing this in anterior teeth poses challenges. TECs may exert increased flexural forces, leading to heightened strain at the crown-root junction and elevating the risk of tooth fracture, particularly as significant dentin removal occurs in the pericervical region. Therefore, a shift toward minimal access cavity preparation is imperative.

In conservative access cavity preparation, the approach involves a 1mm anatomic flattening, employing a penetration angle less than 45 degrees until reaching the dentinal map. This is achieved through the utilization of more conservative CK micro endodontic access preparation burs. Aligned with the principles of "minimal invasive endodontics", this technique aims to avoid excessive enlargement of the radicular dentin, recognizing the undesirability of such enlargement in preserving tooth structure.⁽¹³⁾

Newer designs of access cavity preparation:

- Conservative endodontic access cavity
- Ultra conservative access cavity / 'Ninja'
- Orifice-directed dentin conservation access cavity / Truss
- Caries driven

- Restorative driven
- Cala Lilly enamel preparation
- Image-guided endodontic access
- Dynamically guided endodontic access
- Micro-guided endodontic access



4. Minimizing tooth preparation:

Optimal selection of a crown type should prioritize the patient's well-being, taking into account functional necessities, the stability and vitality of the tooth structure, and considerations for aesthetics and individual morphological characteristics of each tooth. Metal crowns offer the advantage of requiring a minimal preparation depth (0.4mm). In contrast, ceramic crowns, composites, or combinations of these materials with metal necessitate a deeper preparation (1.5-2mm), thereby posing an increased risk of adversely affecting tooth structures or functions over the long term.⁽¹⁴⁾

Therefore, the strategic approach involves minimizing the extent of dentin removal during tooth preparation. This is achieved by preserving the RDT through the use of minimally invasive instruments. Such an approach serves to maximize the strength and resistance to fracture of teeth, aligning with the overarching goal of ensuring the patient's dental health and longevity.

DISCUSSION: The significance of RDT in dentistry is a crucial consideration in various dental procedures, particularly in context to tooth preparation for restorative interventions. Maintaining an adequate RDT is essential as it influences the mechanical stability and strength of the restored tooth and preserving the vitality of dental pulp. Insufficient RDT can compromise the structural integrity of the tooth, leading to increased susceptibility to fractures and other mechanical failures. Excessive removal of dentin can result in pulp exposure and potential damage, leading to postoperative sensitivity.

In prosthodontics, the significance of RDT extends to the design of fixed or removable prostheses. Adequate RDT is necessary for ensuring proper retention and stability of prosthetic appliances, minimizing the risk of complications such as prosthesis debonding or fracture.

In endodontics, RDT is closely linked to the prevention of procedural complications. Maintaining an appropriate thickness of dentin helps prevent iatrogenic errors, such as perforations or ledges, during the instrumentation and obturation phase of root canal therapy. These complications can significantly impact the success of the treatment.⁽¹⁵⁾

CONCLUSION: The significance of residual dentin thickness in root canal treatment encompasses its role in maintaining the structural integrity of the tooth, preventing procedural complications, preserving pulp vitality, and supporting the success of subsequent restorative interventions which cannot be ignored. Specialists must carefully assess and manage RDT to optimize outcomes and enhance the overall health and longevity of the treated tooth.

REFERENCES:

1. Tomer AK, Miglani A, Chauhan P, Malik N, Gupta A. Residual dentine thickness. *Int J Appl Dent Sci*.
2. Lancaster PE, Craddock HL, Carmichael FA. Estimation of remaining dentine thickness below deep lesions of caries. *Br Dent J*. 2011 Nov;211(10):E20–E20.
3. Kamal RP. Estimation of Remaining Dentine Thickness (RDT) Under Caries Lesion with a Cone-Beam Computed Tomography and Standardized Paralleling Technique in Comparisons to Actual Measurement. In Vitro Comparative Study. *Int J Clin Stud Med Case Rep [Internet]*. 2021 Aug 4 [cited 2023 Dec 2];11(5). Available from: <https://ijclinmedcasereports.com/ijcmcr-ra-id-00274/>
4. AL-Jhany N, AL-Hawaj B, AL-Hassan A, AL-Semrani Z, AL-Bulowey M, Ansari S. A comparative evaluation of the estimated radiographic remaining dentin thickness with the actual thickness below deep carious lesions on posterior teeth: An in vitro study. *Saudi Dent J*. 2019;31:S36.
5. da Silva GSQ, Raggio DP, Machado GFR, Mello-Moura ACV, Gimenez T, Floriano I, et al. Impact of different restorative treatments for deep caries lesion in primary teeth (CEPECO 1) – study protocol for a noninferiority randomized clinical trial. *BMC Oral Health*. 2019 Jan 8;19(1):6.
6. Razumova S, Brago A, Barakat H, Serebrov D, Guryeva Z, Parshin GS, et al. Evaluation of Dentinal Thickness and Remaining Dentine Volume around Root Canals Using Cone-Beam Computed Tomography Scanning. *Dent J*. 2023 May 4;11(5):124.
7. Bandlish RB, McDonald AV, Setchell DJ. Assessment of the amount of remaining coronal dentine in root-treated teeth. *J Dent*. 2006 Oct;34(9):699–708.
8. Balagopal S, Bejoy Mony C, Hemasathya B, Nazrin M, James V, Sebatni A. Evaluation of remaining dentin thickness around the prepared root canals and its influence on the temperature changes on the external root surfaces during different heated gutta-percha obturation techniques. *Indian J Dent Res*. 2020;31(6):857.
9. Berani R, Sveqila M. Remaining Dentine Thickness Following Tooth Preparation And its Impact on Dentine – Pulp Complex. *Int J Bus Technol*. 2018 Jan 1;6(2):1–8.
10. Kulkarni N, Kamat S, Hugar S, Nanjannawar G, Patil P. Evaluation of remaining dentin thickness following use of three different rotary nickel–titanium retreatment files: A cone-beam computed tomography study. *J Conserv Dent*. 2019;22(6):588.
11. Kiran NK. Clinical Evaluation of Polyamide Polymer Burs for Selective Carious Dentin Removal. *J Contemp Dent Pract*. 2009 Jul;10(4):26–34.
12. Green ME. The Effect of Instrumentation Taper on Dentin Conservation.
13. Kumar T, Mittal S, Keshav V, Kaur R, Maakhni E. A comparative evaluation of remaining dentin thickness following biomechanical preparation of teeth using different rotary file systems: An in vitro study. *J Conserv Dent*. 2022;25(1):32.
14. Vorster M, Van Der Vyver P, Paleker F. Remaining dentine thickness following preparation with different glide path techniques in combination with WaveOne Gold Primary File. *South Afr Dent J [Internet]*. 2019 [cited 2023 Dec 2];74(10). Available from: <http://ref.scielo.org/k9xt76>
15. Dablanca-Blanco AB, Castelo-Baz P, Miguéns-Vila R, Álvarez-Novoa P, Martín-Biedma B. Endodontic Rotary Files, What Should an Endodontist Know? *Medicina (Mex)*. 2022 May 27;58(6):719.